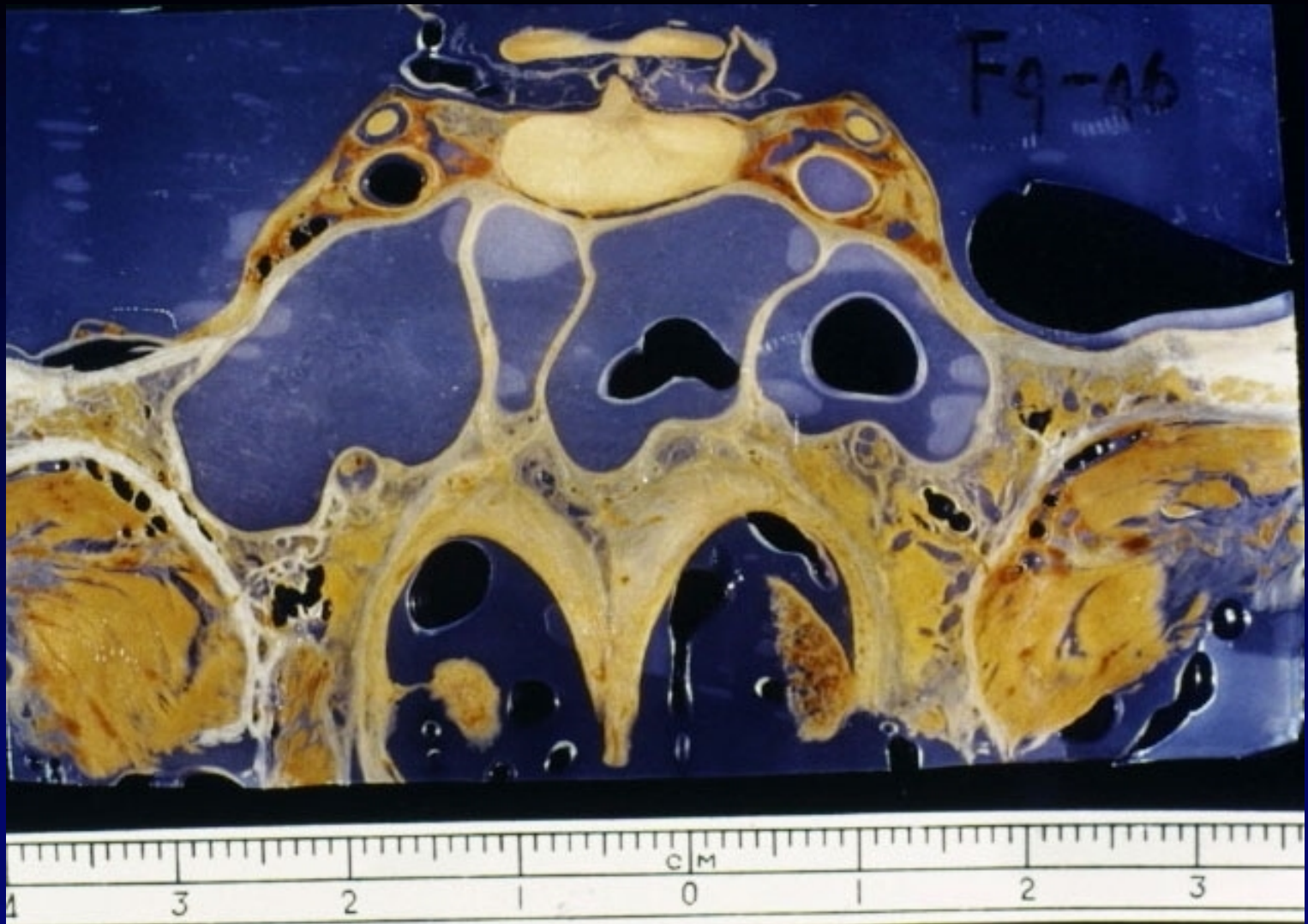


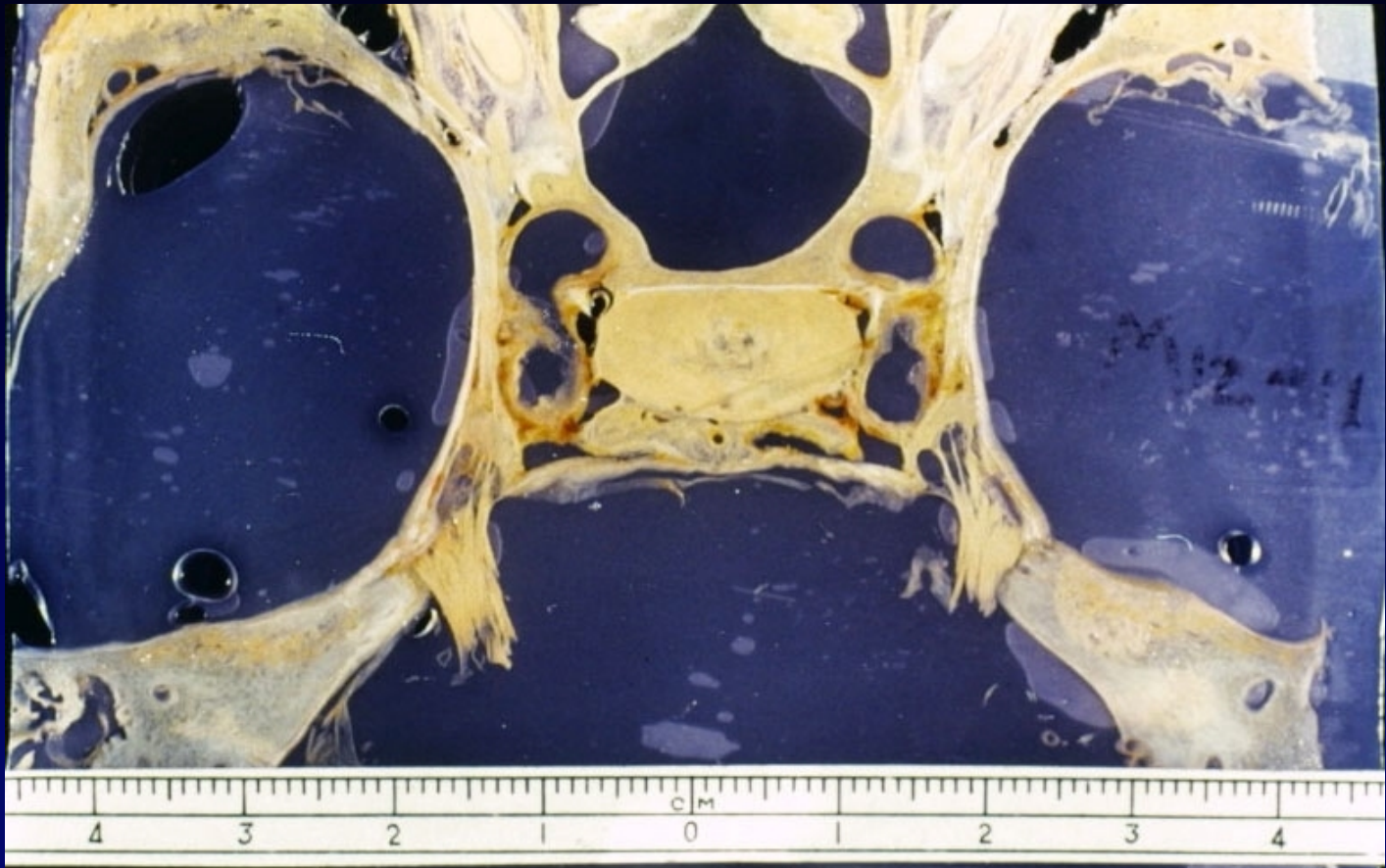


关于海绵窦病变影像学诊断

海绵窦断层解剖

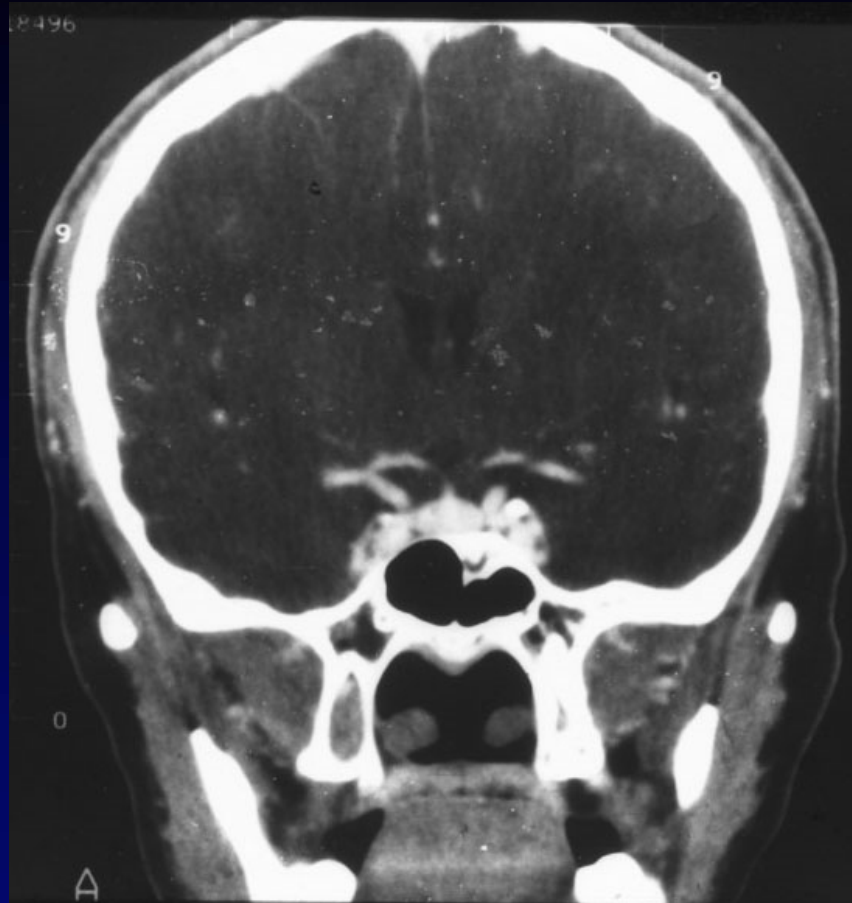


解剖 垂体前叶冠状断面

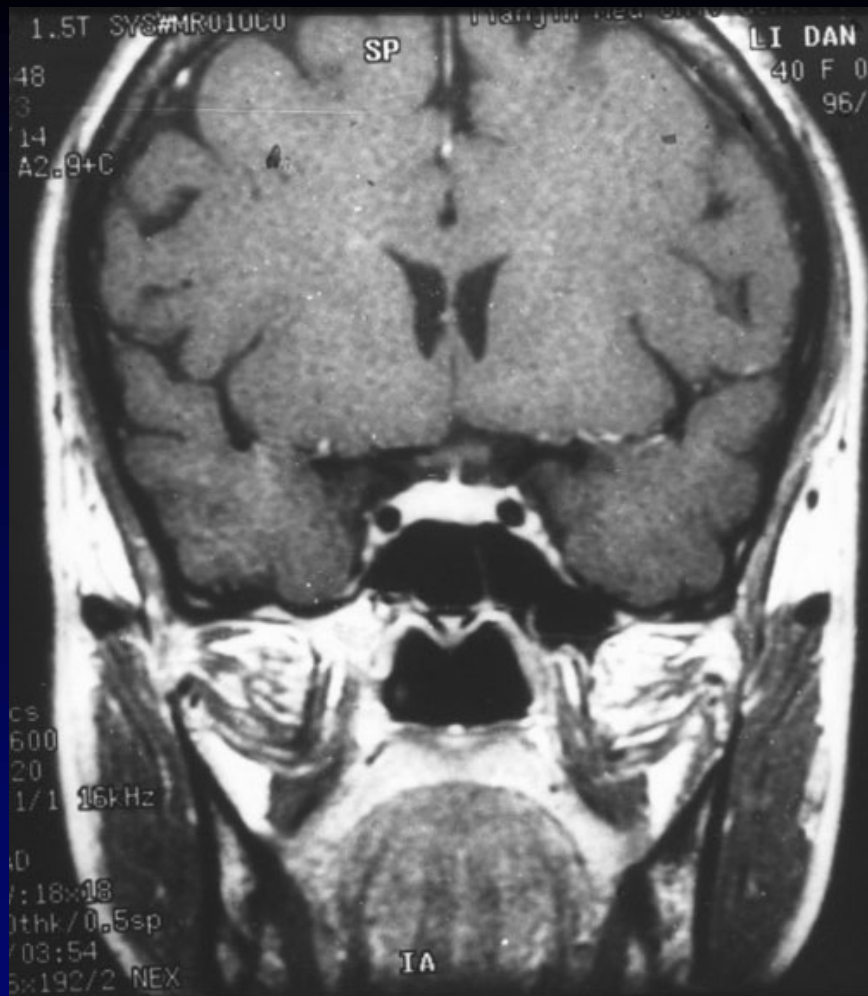

解剖 垂体中部横断面

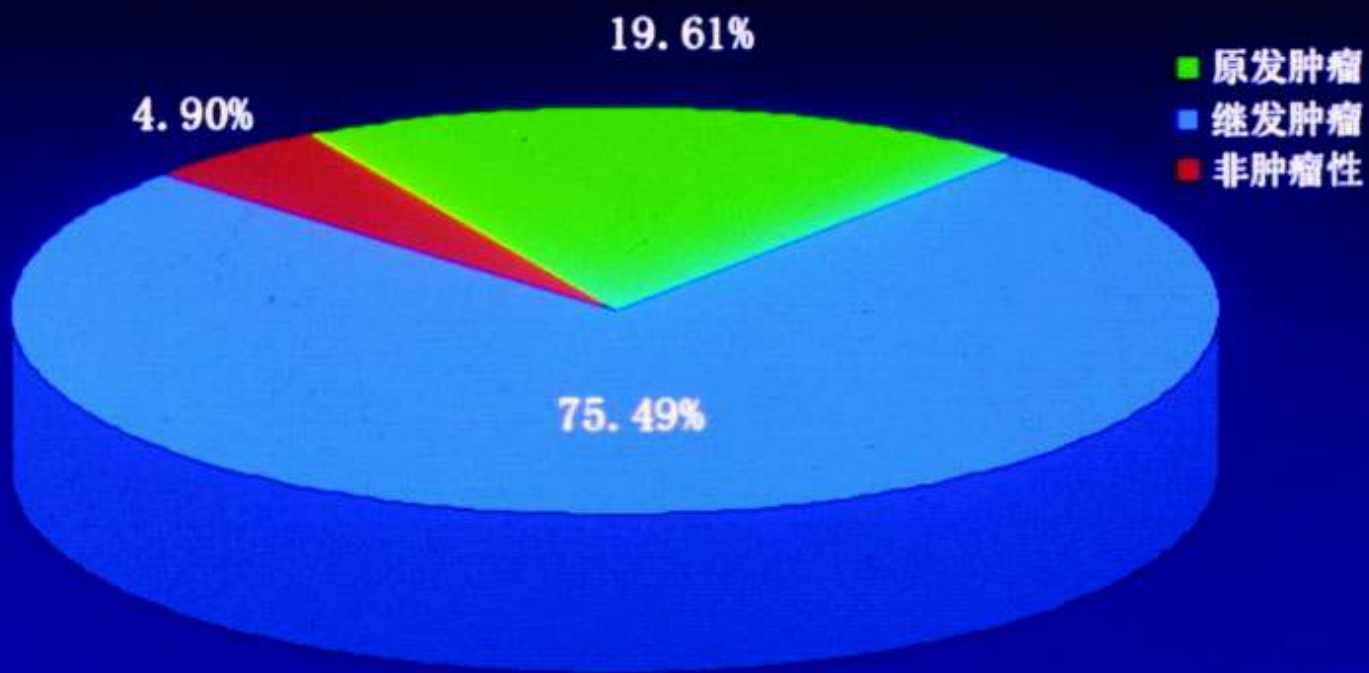
正常海绵窦断层影像



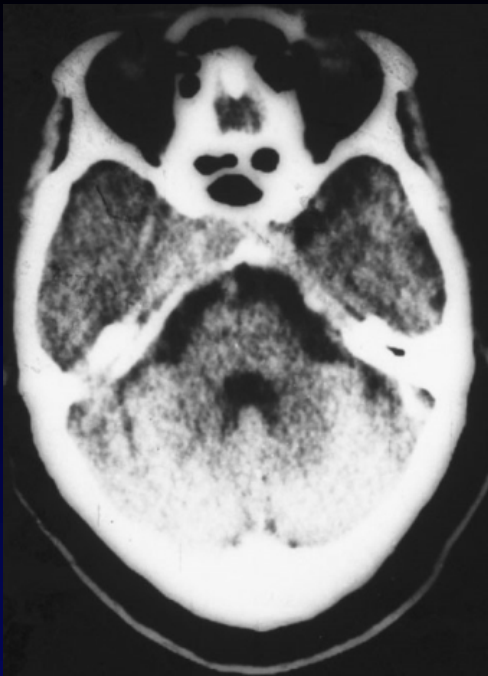
CT +C 冠状断层



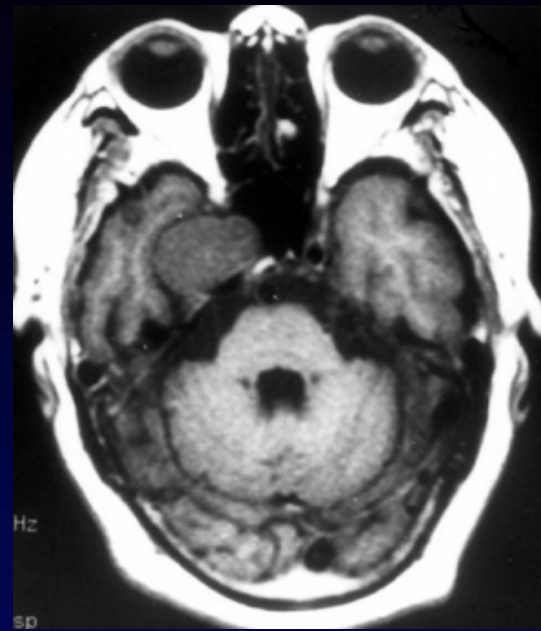
MRI 冠状断层 T₁WI C+



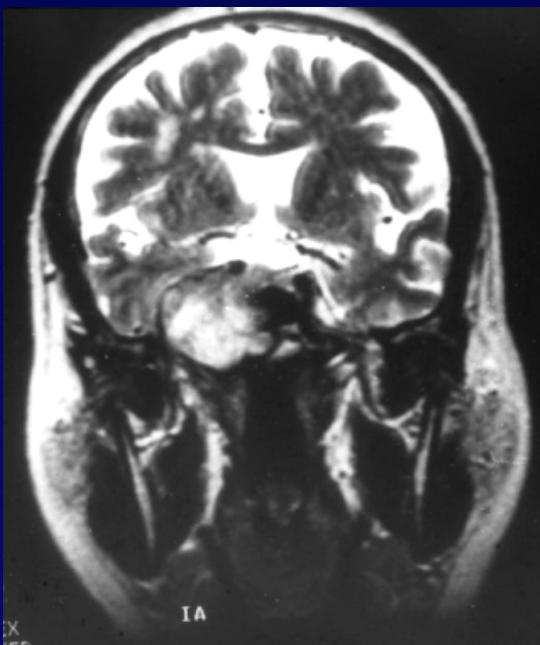
CS病变构成



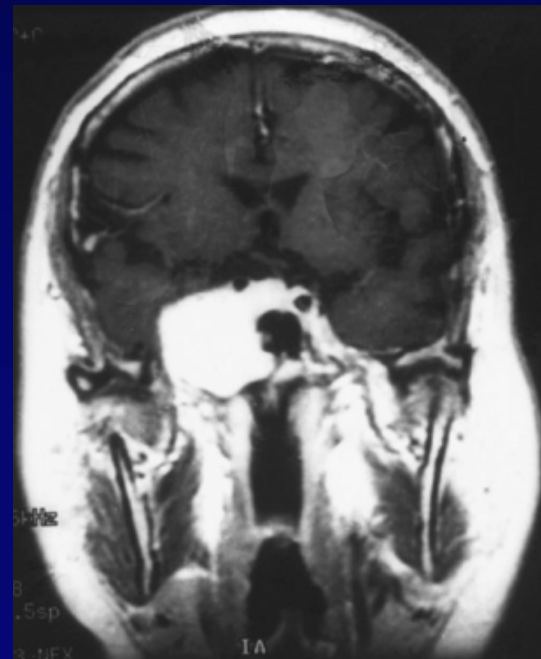
CT平扫



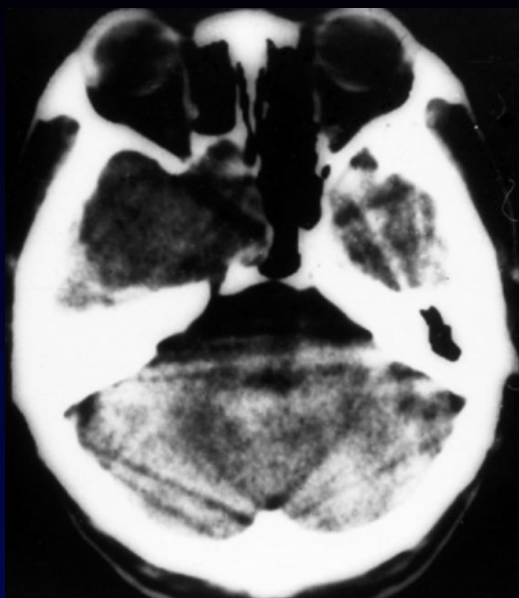MRI
T₁WI



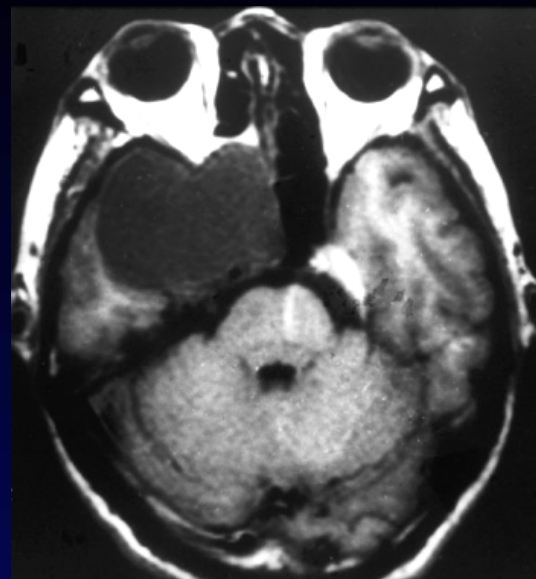
MRI
T₂WI



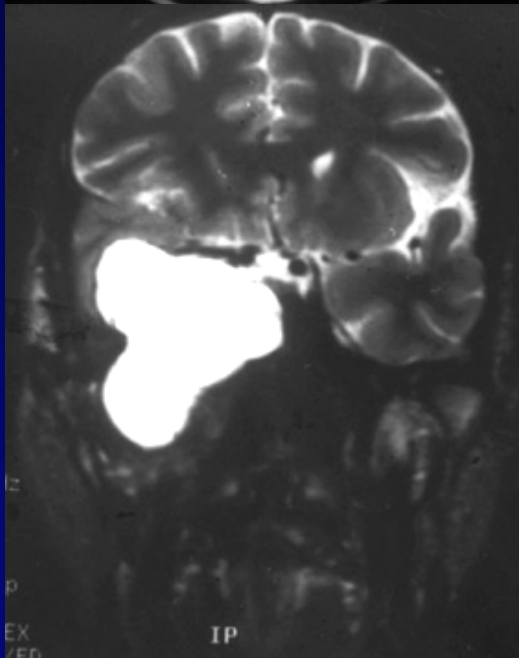
MRI
T₁WI C+



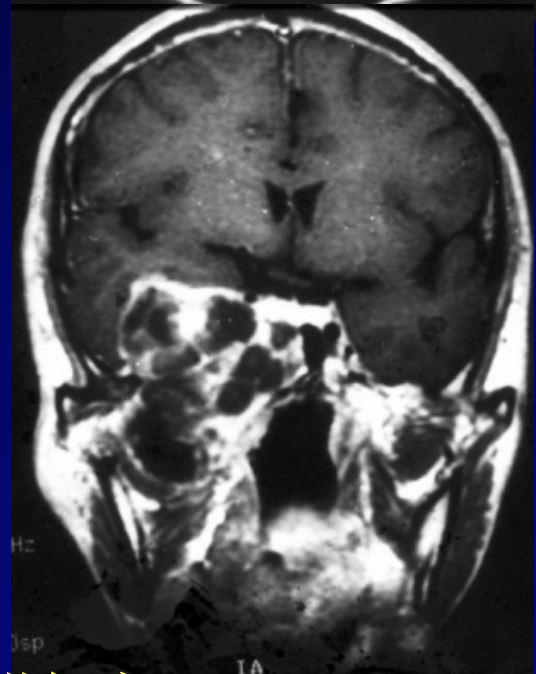
CT平扫



MRI
T₁WI

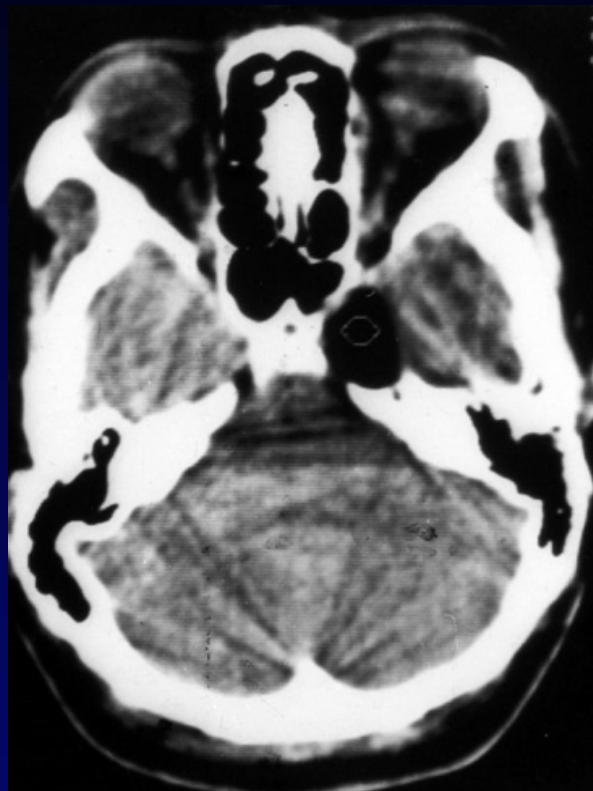


MRI
T₂WI

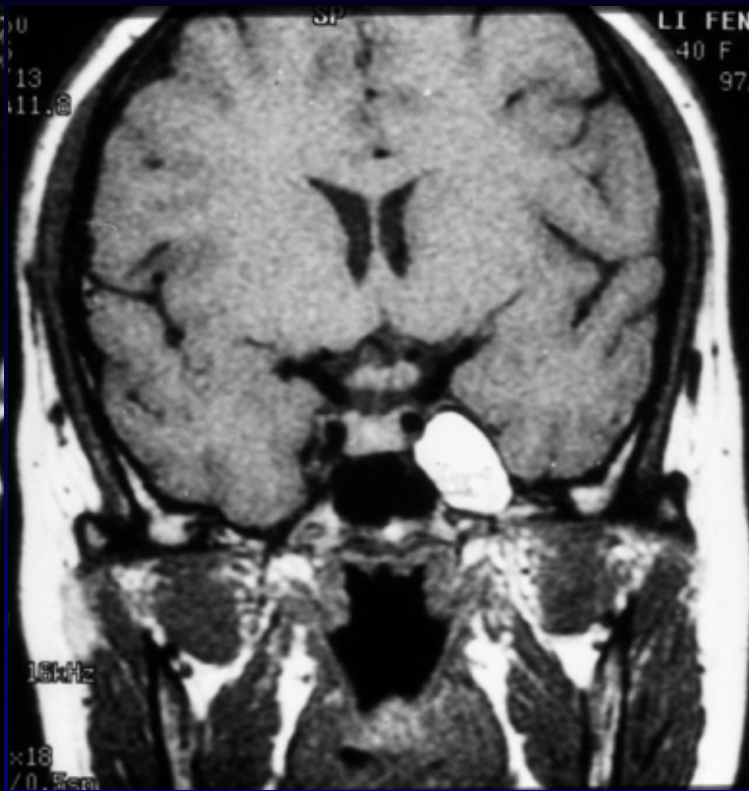


MRI
T₂WI
C+

右三叉神经鞘瘤

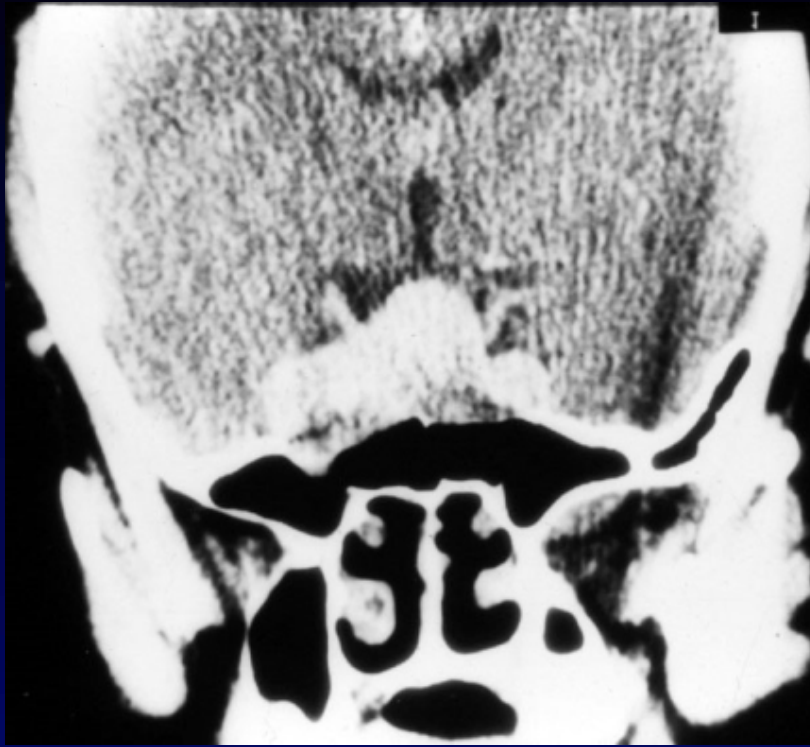

CT平扫

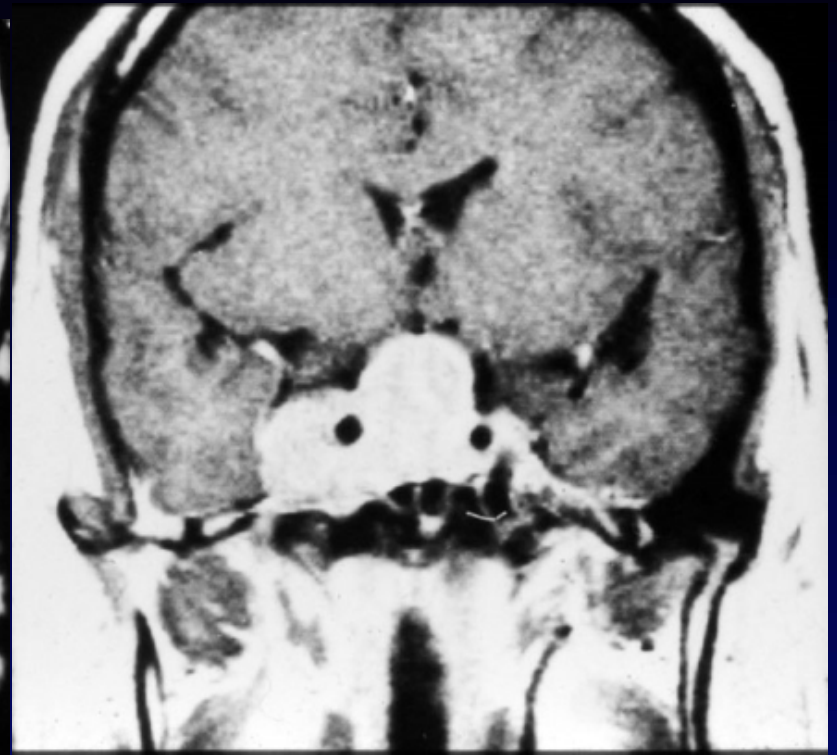


T₁WI

左鞍旁皮样囊肿

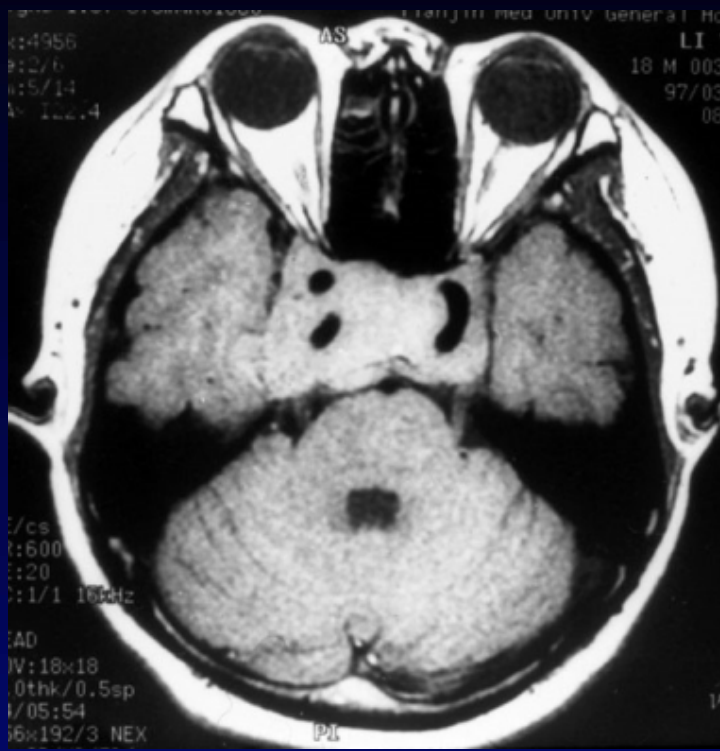

CT C+

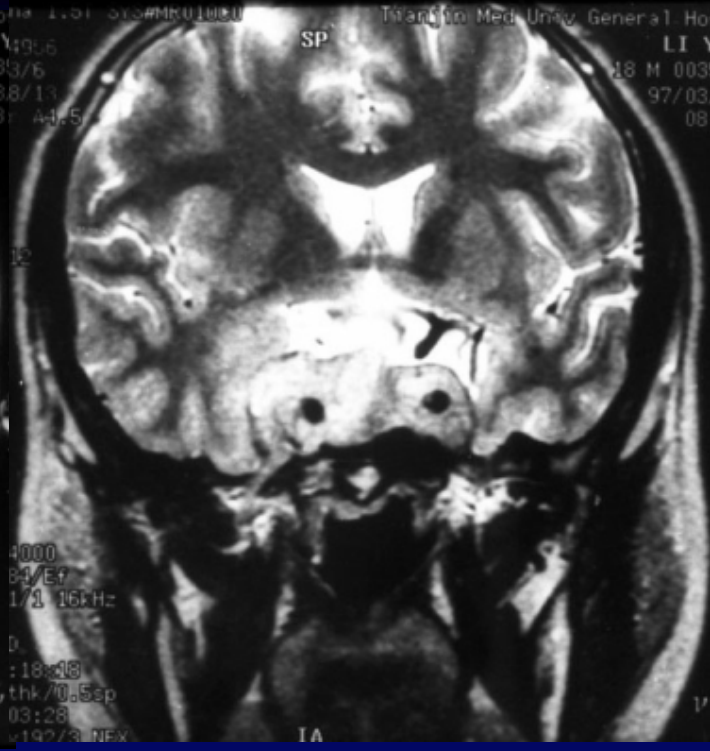


MRI T₁WI C+

垂体瘤侵犯两侧海绵窦



MRI T₁WI



MRI T₂WI

垂体瘤侵犯两侧海绵窦

以上内容仅为本文档的试下载部分，为可阅读页数的一半内容。如要下载或阅读全文，请访问：<https://d.book118.com/388112017121007005>